


# Resident REVIEW

CUTTING EDGE ORTHOPAEDIC INFORMATION ENHANCING RESIDENT EDUCATION

March 2012

## From the Editor, Steven L. Frick, MD



Welcome to the March 2012 edition of the POSNA Resident Review. The educational process you are undergoing as a resident in orthopaedic surgery is undergoing substantial changes; as a program director, I am very familiar with many of them, one of which is the ACGME Milestones Project. I am involved in the process of creating "milestones", meant to assist program directors in assessing achievement by orthopaedic surgery residents of the knowledge, skills and attitudes necessary to competently address specific orthopaedic problems. Hopefully you have found some mentors from medical school and residency to help you in your career. One of my mentors, Richard Gross, is passionate about resident education, and has often helped me frame and understand important issues related to residency education. Below are some comments he shared with me recently about measuring milestones in orthopaedic residents:

*Here I set in writing some thoughts on "milestones", or more broadly, what concepts and tenets as "educators" we should grasp to introduce our residents to the art of surgery.*

*"Art" is a deliberate choice, because it reflects an alternate approach to*


*Continued on page 8*

## Clinical Focus Topic: Legg-Calve-Perthes Disease 2012 Update A Conversation with Harry Kim, MD

By: Tom McPartland, MD

Legg-Calve-Perthes' is a 'peculiar affliction' of the hip in which there is bony collapse of the proximal femoral epiphysis after avascular necrosis. Despite much careful clinical research, no specific mode of treatment has proved to be consistently effective at preventing long term femoral head deformity. I spoke with Harry Kim, MD about his career as a pediatric orthopedic surgeon and translational research scientist, with a very specific focus on understanding the biology of Legg-Calve-Perthes' disease and the development of new treatment strategies. Dr. Kim is the Director of Research and the Director for the Center of Excellence in Hip Disorders at the Texas Scottish Rite Hospital in Dallas, TX. He is a recipient of the Arthur Heune Memorial Award for Excellence and Promise in Pediatric Orthopedics, four(4) Best Basic Science Paper Awards at the POSNA annual meeting, the St. Giles Young Investigator Award, and the AAOS-OREF Travelling Investigator Award, among many other honors.

*Dr. Kim, thank you for taking the time today to speak with me about this problem which has perplexed pediatric orthopedists for decades.*



Harry Kim, MD

*When you first looked at LCP disease as this enigmatic problem and broke it down in to its component parts, what was your initial understanding of the problem going into your research? What could you take for a given?*

I started to study this area (15 years ago) at Shriner's Hospital in Tampa and before that at Toronto Sick Kids. I worked with Dr. (Robert) Salter who contributed significantly to this field. When I looked at this question, what was not clear is why the femoral head was deforming. This question arose because we could not accurately predict who would do well and who would not do well. A poor outcome was defined as the femoral

*Continued on page 2*

# Clinical Focus Topic: Legg-Calve-Perthes Disease 2012 Update

A Conversation with Harry Kim, MD

*continued from page one*

head deforming significantly. The literature suggested the problem lay in the healing process (resorption and lack of anabolism). There was large knowledge gap. We had good clinical information but the understanding of biology was missing.

We can't take specimens from patients, so the information on how healing progressed was limited in humans. That's why we turned to animal models to understand why the femoral head deforms after losing blood supply. This gave us a clue that there was a biologic response that was pathological. The healing process contributes to the pathology. This may be a target area for improvement in treatment.

(The piglet has become a well studied model for LCP because of its similar epiphyseal circulation and, more importantly, it mimics the progression through fragmentation and reossification that occurs in humans).

One of the first things we could identify is that a lot of bone resorption would take place. And there is also not enough new bone formation. There is an imbalance between resorption and bone anabolism. This led to the thought of using an anti-resorptive agent (bisphosphonate) and then later using a bone anabolic agent (BMP-2).

(Dr. Kim's group published a paper in JBJS May 2011 on combining ibandronate and BMP-2 and it improved healing and decreased deformity in the piglet model)

When I started, the first issue was understanding the deformity (and its pathobiology). We have a better grasp on this now. Now the target is to find ways to modulate the healing process.

*Many articles describe principles of "containment" for the clinical treatment of Perthes' disease.*

*Physical Therapy, splinting, and adductor tenotomy have been used to maintain range of motion.*

*Varus femoral osteotomy, Salter's innominate osteotomy, and other procedures like the shelf osteoplasty have been applied in certain groups or when there is extrusion of the hip. How do these clinical practices fit into this evolving understanding of Perthes' disease?*

Another thing I think is important is that Perthes' (disease) is complex - there is this pathobiology but there is also an effect by the mechanical environment. The femoral head is diseased and the child continues to load it. If you continue to load a femoral head with total (epiphyseal) involvement, regardless of what you do to biology, you will still get a deformed head. It takes time for the head to heal, and unless it is protected during that healing phase then it is going to fail mechanically.

*How does weight bearing factor in here?*

So we have studied in the experimental model the role of weight bearing in this process. We found it contributes significantly to the deformity. What we think needs to be done is the patient needs to be locally non-weight bearing or more specifically toe- touch weight bearing with crutches, not at bedrest. Because compliance can be difficult, we probably need to add a biologic to accelerate the healing phase. The goal would be to minimize the duration of fragmentation and maximize healing and reossification so you can reduce duration to 6 months or less.

(Perthes' disease fragmentation phase can last up to 2 years in some children which affords more time for the femoral head to deform. We are forced to limit kid's activities for a long time)

*Your group has shown the promising effect of bisphosphonates (ibandronate) in preventing bone resorption in LCP. How did you select BMP-2 as the bone anabolic agent to accelerate healing? What were its promising properties?*

We were attracted to BMP-2 for its excellent osteogenic potency. It was readily commercially available, although in an off label indication. In addition to its osteogenic potential, BMP-2 also stimulates new blood vessel growth, which is an attractive property in avascular necrosis. BMP is very potent and there is a risk for development of heterotopic ossification and we have seen this in our animal model. It needs to be used judiciously and you want to use minimal dose without side effects. In our study in JBJS 2011, BMP led to bone formation, but the animals got heterotopic ossification in the hip capsule in all animals.

*So this brings up the question of delivery. Do you see any promising technology for this agent to keep it in the epiphysis?*

So that's an active area of our research. How can we deliver (effectively) and decrease the dose to reduce complications. So when we first did it, we pushed the drug in. Now we infuse with a pump over a twenty-minute period. The other thing would be to use a biodegradable (delivery system) to keep the drug contained. It will take some time to figure out what will be the optimal way.

*Do you potentially see some form of surgical intervention to deliver those biologicals?*

I think so. So when you look at Dr. Herring's Work and Dr. Wiig's work from Norway, the femoral osteotomy seems to have an effect in certain age groups on outcome, but the effect is

*Continued on next page*

# Clinical Focus Topic: Legg-Calve-Perthes Disease 2012 Update

## A Conversation with Harry Kim, MD

*continued from page two*

modest when looking at head shape (Stulberg outcome), so we can potentially use a biological along with femoral osteotomy to further improve the results and to make the good results more consistent. That's the (current) problem; we do surgery and don't get the consistent result. We are succeeding 40-60% of the time but we'd like to be 85-90% successful.

*So what's the optimal approach to treating Perthes' disease as you see it now?*

Optimizing the mechanical protection while modulating and stimulating the healing process using biologic agents is the more broad approach to it. For last 50-60 years we've been focused on containment- I think it works to some degree but, a pure mechanical approach, I think, is insufficient to get good results on everybody. I think to have more effective treatment, you need to deal with the mechanical aspects of the disease but also biological aspect. By combining both approaches we will probably get better results.

*How do you see the research in LCP translating to adult AVN? It is a little bit of a different problem. Remodeling potential isn't there. Can we augment core decompression with biologics?*

To some extent I consider our adolescents in that group. I see issues with poorer angiogenesis. Regardless of what you do in young kids, new endothelial cells and vascular granulation tissue migrates into the necrotic bone; this does not occur in adolescents and adults. Core decompression and vascularized fibula are a good idea because you are bringing in new blood vessels. I think the issue is you have to consider the mechanical aspects. If the patient starts to weight bear too early you have too few cells to detect microdamage and repair the process and you develop microcracks

in necrotic bone and these fatigue points become a macrofracture. We must consider the biology and try to promote angiogenesis and speed up new bone formation. So the concept is similar in that we may need to modulate biology and also consider mechanical treatment.

*I'm sure it's difficult to structure your methodology so you are not trying to move too quickly on something that is new and exciting, but really study it rigorously and make sure you are not changing too many variables at once. In my mind, that is one of the hardest things that you as a basic science researcher do. How do you stay focused when it takes years to see changes?*

It's quite difficult. When patients come in, you often wish you had a treatment you could apply that you believe will work, but it is still in the lab. You would not take an unnecessary risk with patient. It is important to make sure you take cautious steps and not rush into clinical applications. We are starting to use biologicals in very selected patients. This is the way it needs to be done in the initial phase in order to determine what is the best surgical approach, best dose and application technique for biologicals.

*Do you have any advice to aspiring pediatric orthopedists who are interested in research?*

Research adds to pediatric orthopedics, being able to find ways to improve understanding of our diseases and improve treatments. We as practitioners and surgeons ask these questions and try to get answers. I don't think there are other people (basic science researchers) out there who understand the disease and feel passionate about it, because we are the ones actually treating patients. Every day when I go to the clinic, I feel the urgency to try to find the answer. That child wants to

get back to playing sports. The parents want the child to have the full experience of childhood instead of being left behind for a couple of years to have the disease heal. For me, you definitely make more impact (by being involved in research) even though it can be a slow process. I was very fortunate to work with Dr. Salter, and identify a good animal model to study this condition. I had great institutional support at Tampa Shriners' and then here at TSRH.

*How much time do you dedicate to research and to clinical patient care?*

I have one day per week in clinic and four days a week for research. I am now the director of research and get involved in the development of studies in collaboration with other docs at TSRH.

*Do you have anything else you want to share with us Dr. Kim?*

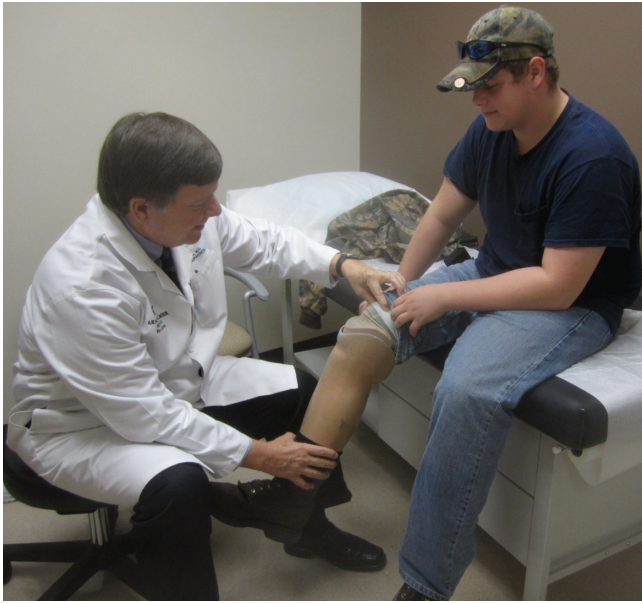We are having the first International Perthes' Study Group here in Dallas March 8-9. Fifty centers are participating. We can do a multi-center prospective cohort study and within 2-3 years as we can get a better idea of patient volume and potential recruitment rate. We are thinking about doing a randomized clinical trial on bisphosphonate treatment as an adjuvant or supplement to varus osteotomy, with blinded placebo controls. This would improve significantly on previous study designs and hopefully give us the power we need to answer some of these questions.

We will all certainly look forward to the forthcoming data and hope for some new methodologies for treating Legg-Calve-Perthes disease in the near future. I thank you for your time and your important contributions to pediatric orthopedics.



# An Interview with Dr. Chad Price

By: Pablo Castañeda, MD



*Chad Price, MD with patient*

*Please tell me about your early life and whether this had any influence on your ultimate career choice as a pediatric orthopedic surgeon.*

I think all those things influence you in ways you don't appreciate at the time. I was fortunate to be exposed to medicine early in my life with my father being a surgeon. I knew what it meant to be a doctor and even back then it was pretty grueling but it appealed to me. I didn't know that I wanted to be an orthopedic surgeon until I finished med school.

I went to Baylor in Houston which was terrific. It was one of the first schools to do integrated teaching, and I was exposed to orthopedic surgery as well as general surgery. We got to do a lot of surgery, which was one of the most appealing aspects of it.

I grew up in Central Florida and after my time in Texas I came back home to do my residency at the University of Florida in Gainesville and did my orthopedic residency program with Bill Enneking. I was considering sports medicine but somehow I got turned on by the kids because they

didn't have so many self-inflicted injuries and they seemed to do better than the adults did.

I was born and raised in a little town in the middle of Florida, before there was air conditioning and there weren't many roads to get there. It was mostly cattle and citrus, an agricultural town with about 80,000 people. We did a lot of hunting and fishing, and I considered it a rural community even when I graduated from high school in

1963. Then Disney came to that little town in 1971, and that town is now Orlando. So I grew up in Orlando, but like to think I grew up in a small town and Disney just happened to us. I was very fortunate to grow up in this great place and then come back afterwards. You really couldn't have practiced pediatric orthopedics in Orlando when I was a kid, and seeing the change has been fascinating and has turned out great.

I did my fellowship with Wood Lovell in Atlanta, which is about as far north as I ever got in my career- I think it actually snowed that year... It was unusual because it was a time when most people weren't doing formal fellowships. I was supposed to go to Vietnam, but the war was winding down, and 2% of the enlisted were released from their obligations. I was one of the 2%, but I didn't know that until 6 weeks before my residency ended. I had a wife and 2 kids and no place to work and my plans were to go into the military. Fortunately for me, Wood Lovell took an extra fellow in that year and I am forever indebted to him for giving me a job in addition to the great training. So when I came

back to Orlando I had a fellowship, and people started sending me really complex stuff.

*You have had a fantastic career. Do you have any insight into the evolution of pediatric orthopedic surgery?*

Let me start by saying that I think the future is very bright. Early in my career everyone did pediatric orthopedics, and the pediatric orthopedist was the tertiary referral specialist who took care of the really difficult stuff: cerebral palsy, spina bifida, limb deficiencies. I mean the worst of the worst; but clubfeet and hip dislocations and fractures were taken care of by general orthopedic surgeons, so you only needed about one pediatric orthopedic surgeon for every 500,000 people. But then we became the orthopedic surgeons for everyone under about 14 years, but we were still doing everything: spine, hip, foot; the procedures weren't so complex that you couldn't master them all and that was tremendously fun.

Now it seems to me that there is a good trend in subspecialization, while there is still a definite role for a general pediatric orthopedic surgeon. Those of us in academic practices often don't see how great it can be to have a private practice. When I was coming along you could really only practice pediatric orthopedics in an academic setting, but now you can have a successful practice and take care of fractures and SCFE and Perthes disease and scoliosis and do all sorts of great procedures, and send the really complex stuff like skeletal dysplasias and limb deficiencies to a big center. There is a lot of gratification in being a community pediatric orthopedic surgeon, but you also have an opportunity to subspecialize and be a hip surgeon, a sports surgeon, a spine

*Continued on next page*

## An Interview with Dr. Chad Price, *continued from page four*

surgeon. There are a lot more choices now in pediatric orthopedics and that is a good thing.

### *What is your current practice like?*

I currently work with a 7 man group and there is more subspecialization within the group. One of the great things about pediatric orthopedics is that you do get to operate on the whole body and do spine, lower limb, upper limb, and even benign tumors. Within our group everybody still does everything, but for some of the more complex things like cervical spine, one person who will do that.

My practice over the last couple of years has been focusing more on the nonoperative side of things, and I've been seeing more scoliosis and hips from the nonoperative angle. That's been a lot of fun for me.

I think when you're starting out you don't want to restrict yourself, but as you get older you can focus on a more narrow target, and it can be increasingly fun because you get to do more and more of the things you really want to do. At first you want to do everything but as you get older you want to focus on specific things. So my practice now is more academic, and I am taking things a little bit more thoughtfully.

I don't take call anymore, which is a good thing, but even that has changed so much, with cold trauma and taking care of things within the subspecialty group. It has allowed us to improve our lifestyles and our ability to take care of patients.

So I think it's an exciting time to be a pediatric orthopedic surgeon.

### *What's the most rewarding or stimulating aspect of what you do now?*

The beauty of orthopedics is it you get a lot of immediate gratification;

you go and you fix something and immediately you can tell whether you did a good job or not; but also in pediatric orthopedics you get a lot of delayed gratification. So to me the beauty of pediatric orthopedics is you get this mix of both immediate and delayed gratification.

Right now in my practice the delayed gratification is by far the biggest piece for me. Having lived and practiced in the same place my whole career, it's kind of hard to describe the relationship you get with someone who you have been taking care of for 30 years. They invite you to their wedding, and send you e-mails from college, and invite you to their graduations; and sometimes it seems like a bit of a burden at the time when you're busy and you have a lot of stuff going on, but it gives you a chance to see what an impact you have had on peoples' lives and how important you have been to them. It is very humbling that people put that much trust, confidence and faith in you. That part just comes to life later in your career. I certainly didn't appreciate it as much before as I do now.

---

***"I treasure being a doctor, and an orthopedic surgeon who takes care of kids and can make a meaningful difference."***

---

Earlier in my career I was just thrilled to be taking care of people and doing these procedures which were so much fun to do. I thought I was doing a good job, but when people you have been taking care of start to have these tremendous achievements, like becoming a PhD or many other accomplishments, which they could not have done without your help, then it allows you perspective on why you went into pediatric orthopedics in the first place.

The other really great thing about our specialty is when you're starting out in your career, the non-operative

side tends to be less attractive - you really want to be doing things in the operating room but clinic is really only the place you go to find the cases and the patients you want to operate on. Then later on you find you can really enjoy clinic and the nonoperative aspect of taking care of patients. As a counter example, if you are cardiac surgeon, or even a total joint surgeon, you're either in the operating room or retired, whereas a pediatric orthopedic surgeon can really enjoy the other aspects of taking care of patients.

So the opportunities to continue doing what you like doing are always there. Now, I enjoy the intellectual challenge and analysis of the decision-making process - it is much more intriguing to me; I'm in a more cognitive mode.

Don't get me wrong, the surgical skills and the enjoyment of doing the procedures were my favorite part of my career- but in your more senior years the intellectual challenge and the interaction with patients and their families in clinic is very meaningful. We are fortunate that we can shift

gears later in our careers and take advantage of all that.

### *Is there a secret to balancing a family life with the successful career?*

Well I don't think there's any secret in that - it's about having a good marriage or life partner. I don't feel qualified to give anybody marriage advice, because for some people it works out and for others it doesn't. Many many millions of words and books have been written on the subject and I sure wouldn't know

*Continued on page 6*

## An Interview with Dr. Chad Price, *continued from page five*

much about it, other than the fact that I have been extraordinarily fortunate and our marriage has worked.

My wife Pam has been very supportive, and always understood my aspirations and goals. It's not just when you go in to the hospital, and you might spend a little extra time, but it's also about going to meetings, spending time on the weekends reading, writing or working, and just investing time which you might otherwise use for other purposes. It's really important for an orthopedic surgeon to have a partner that understands that you're doing something that you really enjoy and that it's not a burden. You are, to some extent, married to your career also. There is a potential for jealousy and it's important to have a spouse who is willing to share you with orthopedics.

So that's my secret- that Pam has been tremendously supportive and the rest has come pretty easy. We were high school sweethearts and I figured if she could put up with me when I was an adolescent she could put up with me when I was a grouchy old man.

It obviously can't be all about your career- you have to find time to spend with your family with your kids. When I look at most of the successful senior surgeons I have known, who seen the most happy and content, they have all developed some other interests. I think it's important to nurture your other interests outside of medicine.

### *What do you like to do in your free time?*

I have always enjoyed spending time with my kids and my wife. Now that Pam and I are alone, we enjoy playing golf. We didn't really have time for it when the kids were younger, as we preferred to be with them. We really enjoyed doing their activities, and now we enjoy our grandchildren's activities.

I also really enjoy spectator sports; I just went to the 24 hour Rolex race last weekend in Daytona which was very exciting. I enjoy any kind of auto racing, but mostly NASCAR which you really have to experience in person to get the entire feel for it. It's like being at an air show- there is no way to appreciate the speed on the television- but when you're there in person, it is very impressive.

I also enjoy going to football games and basketball games. Both Pam and I are big fans of the University of Florida athletic teams.

### *And your career has allowed you to do these things?*

No question. I think it's true of all areas of medicine that most people have the resources to do things they want to do. The problem sometimes is that we have the resources but we don't always have the time.

And Lynn Staheli said it best: you want to keep your life simple and keep your overhead down, because you risk overburdening yourself with expenses and then you really can't take the time to do the things you want to do.

Pediatric orthopedics has allowed me to travel so much and not just big conferences, of which there are a lot and you can get a lot out of those.

I never dreamed when I went into medicine you can develop so many friendships over the globe- you can go and visit people all over the place. Those avenues are open to almost anyone. If you go to a meeting, you don't have to be in an academic position- you can simply go up to someone, say maybe, from Italy, and say I'd like to come and visit you, and most of the time they are more than happy to host you for a day or two.

One of the most fantastic things about medicine is it allows you to see the

broad-spectrum of humanity, and while in some professions you only deal with one sector of society, as a physician you deal with the whole spectrum- from the cocaine addicted mother who could have beaten her baby, to the wealthy baseball player or the successful businessman whose child has scoliosis or hip dysplasia. If you're observant you can become a very good judge of human nature.

The other thing we sometimes forget is we see people when they're at a time of personal crisis. Having a child ill or injured is one of the most stressful things to ever happen to a person, and for us it's an everyday occurrence. Maybe we'll see 20 or 30 people like that in a day, but for them, it's the most important thing, the only thing they care about; and they are entrusting you to be a part of their lives in this time of need. So we get to see the most beautiful characters, but also some of the worst of human nature, and you can see people who remain calm and become involved in helping with taking care, but also people who get very angry and start placing blame. Sometimes we don't want to take care of those kinds of patients, but if you learn to stand apart from this and observe objectively as a physician, at the end of your career you develop a perspective on human nature which very few people have the privilege to see.

I treasure being a doctor, and an orthopedic surgeon who takes care of kids and can make a meaningful difference.

### *Tell me about your experience with the International Pediatric Orthopaedic Symposium.*

Well, there is a long history, beginning with Mike Tachdjian, who was one of the creators of our specialty. He wrote the first major pediatric orthopaedic text and designed a review course for residents. The course went on for

*Continued on next page*



## An Interview with Dr. Chad Price, *continued from page six*

many years, with a number of us on the faculty, when he died suddenly of a heart attack. There was a question whether we should continue to carry out his tradition. The group got together and decided to stick together as faculty, and for some reason I was chosen as the chairman; so I looked around the room at the faculty he had assembled and it seemed to me we had the opportunity to upgrade a simple review course to a symposium of the highest level.

There is great value in a review course, but it seemed to me that if we could grab the greatest minds and challenge each other, it would produce a better result. Eventually we had enough faculty to have four or five leaders on a certain subject, and let them talk about their most specific interest. If you let them talk, for example, about congenital pseudarthrosis of the tibia or femur fractures, instead of having just one person, we would have five or six of the leading figures discussing amongst themselves and presenting to each other as well as discussing cases. So it became more of a debating society, and that's when the chemistry really kicked in and we realized that everybody was learning. One of the greatest things was increasing the amount of faculty, which made it more vibrant experience.

Now IPOS is a fantastic learning opportunity- anyone from a resident, a fellow or a senior faculty member has a chance to learn, and it has been really fun to watch that grow and develop. Both the AAOS and POSNA have been very helpful with that.

***You are currently involved with the IHDI (International Hip Dysplasia Institute), what has that been like?***

As I said, you get exposed to all sorts of people and one of my patients was the son of the comedian Larry the Cable Guy, who came to me with hip dysplasia. They had a lot of good questions, including why we do things

the way we do, and why other people did things in other ways, and why there was no group or organization like the Scoliosis Research Society that was really looking into this. They helped us with the financial resources to put together a reliable group and website. The IHDI was born- we started with seven locations all over the world. One of the things we were able to do was design and carry out an international multicenter cohort study, which is allowing us to have a great database with a patient volume approaching 300. We should get a lot of good data out of that. Another thing that the family questioned was the fact that this condition is really common, yet most people don't know about it, or have maybe heard about it only in dogs, so we began an awareness campaign.

We also knew that unfortunately swaddling has become commonplace in United States, with approximately 82% of mothers swaddling their babies. Even some of the nursery personnel were getting that message wrong, so we wanted to improve public awareness and advocacy, and we plan to expand that have more sites and centers and include people who have an interest in hip dysplasia.

We want to become bigger and more inclusive and do more research. If you go back to Salter in 1968, he advocated prevention. As orthopedic surgeons we figure prevention means early detection and treatment, but he felt like you can actually prevent hip dysplasia if you don't stretch the hips out. There is some evidence from Klisic in Yugoslavia in the 70s, along the same lines, so one of the major objectives of our group is to look into the possibility of true prevention; particularly in underdeveloped regions that don't have access to some of the high end technology of ultrasounds. We think there could be some ways to prevent postnatal dysplasia of the hip, which to me is the big promise of the IHDI.

***Why should a young surgeon considering a career in pediatric orthopedics go into it?***

Because you can pretty much do whatever it is you want to do. I've been fortunate enough to do what I have wanted, but it has still always been a choice. Not everybody has to do all the things I have done to have a great career and have a great life and a great family. You can be a great pediatric orthopedic surgeon in the community, attending courses and practicing at the highest level and you don't necessarily have to be in academicians to have a fantastic career. I have great respect for the community orthopedic surgeon, and there are a lot of people who practice at the highest possible level. You can publish and present at meetings, or you can just take the best possible care of your patients and it is just as rewarding.

So what you choose to be may be more or less visible. I have chosen a more visible career path, but there are a lot of orthopedic surgeons who don't have quite as visible a career, and are still having a very successful career. To me that's the most fulfilling part about pediatric orthopedics- you can do sports, you can do spine, you can do hip, you can be nonoperative, you can take call or not, you can write, you can publish, you can travel you can go to courses, you can run courses; if you don't have a good time in this career it's really only because you didn't do what you wanted to.

The world is wide open to the young pediatric orthopedic surgeon.

This interview has been a lot of fun, it's not often you get a chance to talk this long about yourself to an attentive audience.

## From The Editor continued from page one

*an emphasis on technique, which is a subliminal goal of the milestone approach. It has often been said that one could coach a monkey, or some other primate, to do a surgical procedure. Perhaps, but even the purveyors of milestones would agree they don't want a monkey for their surgeon. Why not? The monkey would certainly have repeatedly practiced the procedure to acquire the necessary technical prowess, or in other terms, been checked off on the milestone for that procedure. No, what even the purveyors of the "milestone" want from their surgeon is the ability to observe what is there in the surgical field, alert to any nuance or clue that something out of the ordinary is in play, requiring the surgeon to use his/her knowledge, skill, and understanding to achieve the desired outcome.*

*In "All Things Shining", one is guided through the ages, pausing to learn what was important in different eras in the quest to live one's life well. Suffice it to say a sense of gratitude, an admirable concept, was emphasized, even using an excerpt from "Pulp Fiction" to illustrate. The concluding portion of the book examines the acquisition of athletic skills, and surprisingly employs some surgical metaphors which I found quite relevant to this discussion. Here are excerpts:*

*Learning a skill is learning to see the world differently. The skilled surgeon, for example, sees something more than a broken and bloody leg; he sees a particular kind of break, one that requires this precise surgical technique to fix it. Likewise, we hear people say the successful running back has "great vision", the point guard has extraordinary "court sense". In each case this means the person's skill at surgery or running or passing allows them to see meaningful distinctions that others without their skill cannot.*

*The master's skill .....involves intelligence and flexibility rather than rote and automatic response. To have a skill is to know what counts.*

*To achieve this kind of vision, which I submit is what we want our trainees to take with them when they graduate and practice, requires more of us than counting cases for milestones, and I further submit that we should gladly accept that task, and shun the mindless busywork of tallying numbers for milestones. It requires an assessment of the resident's knowledge, preparation, and physical capabilities to determine what portion of the case the resident and/should perform. It requires constant feedback from the attending, reinforcing what is valuable, and dissuading the resident from using what is not.*

*That is more work, but the choice is clear – shall we train them like monkeys – with milestones, or as someone we would ultimately be content to become our surgeon or our family's surgeon. That is more difficult, and harder to quantitate, but I hope our specialty's decision makers will accept that challenge.*

-Richard H. Gross, MD,  
Professor of Orthopaedic  
Surgery, Medical University  
of South Carolina

The above comments by Dr. Gross remind me of a favorite Einstein quote that I have always tried to keep in mind when evaluating residents and faculty –

**"Much of what is counted does not count, and much of what counts cannot be counted."**

Perhaps this is what Dr. Gross is talking about regarding "milestones" – it certainly presents challenges to those charged with assessing educational progression and the development of competence in orthopaedic surgery residents. Let me know your thoughts about milestones, and the changes underway in your orthopaedic residency education.

I hope you enjoy this edition of the POSNA Resident Review.

Steven L. Frick, MD  
Steven.frick@carolinashhealthcare.org

## ANNOUNCEMENT:

### The AAP Section on Orthopaedics (SOOr) 2012 "Call for Abstracts" is now OPEN!

For details and submission guidelines visit <http://aap.confex.com/aap/2012/cfp.cgi>

The abstract presentation is part of the two-day SOOr Program held in conjunction with the Academy's National Conference & Exhibition in New Orleans, Louisiana. The Section Program is scheduled for October 20-21 -- keep checking the SOOr web site at <http://www2.aap.org/sections/ortho/> for additional details.

\*\*\*\*\* Residents, fellows, and medical students are STRONGLY encouraged to submit an abstract. Three prizes -- \$1,000, \$500, and \$250 -- will be given for the top three abstracts presented by residents, fellows, and medical students. For background on those awards, please visit <http://www2.aap.org/sections/ortho/ortho-history-rra.htm>

Many thanks to the Pediatric Orthopaedic Society of North America for sponsoring the Section's abstract awards.



# Focus – Pediatric Upper Extremity

## Challenging Cases: What Would You Do?

### CASE #1

An otherwise healthy 2 year old girl presents with a unilateral deformity of the thumb as seen in Figure 1. After surgery, the deformity is corrected as seen in Figure 2. Choose the statement below that is true regarding this deformity.

Figure 1

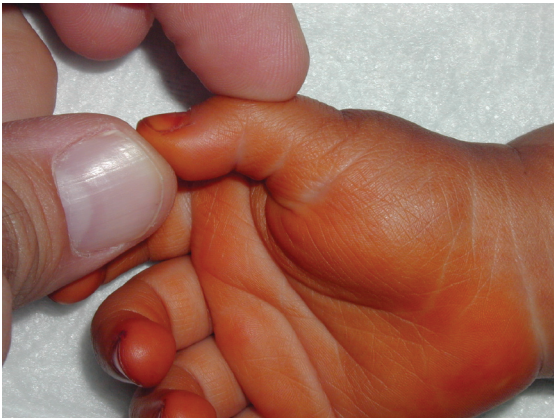
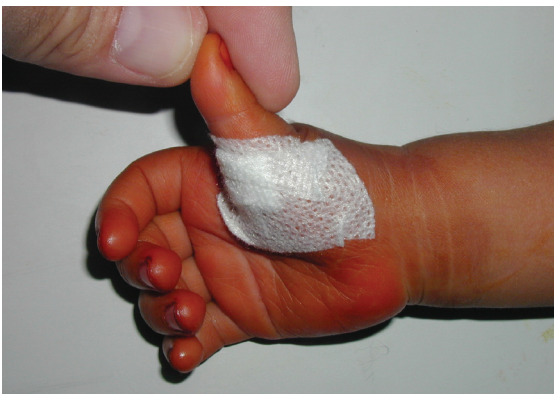
Figure 2



- A. Surgery was not indicated as this deformity always resolves spontaneously
- B. The deformity is congenital
- C. An echocardiogram is indicated as a high percentage of patients with this deformity also have congenital heart defects
- D. A fixed flexion deformity is more common than triggering
- E. Corrective surgery should involve division of the annular pulley and debridement of the nodule in the flexor tendon

Your Response: \_\_\_\_

### CASE #1, continued

#### Discussion

Historical teaching regarding congenital trigger thumb in children recommended observation for 6 to 12 months before surgery, and surgery before age 4 to prevent permanent flexion deformity. These treatment principles have been challenged by subsequent literature. Recent studies have suggested that trigger thumb in children is acquired and not congenital, and that up to 70% of trigger thumbs in young children may resolve, although it may take years, with one study showing the median time to resolution of the deformity being four years. Although commonly called a trigger thumb, triggering is less common and most children present with a fixed flexion deformity of the thumb IP joint that may be mistaken for a fracture or dislocation. Surgical treatment involves simple division of the A1 pulley with excision of the pulley or shaving of any nodule in the flexor tendon; surgery is typically uncomplicated and curative, with return of full extension, even in older children. Trigger thumbs are not associated with any other health problems. Surgeons making the diagnosis can utilize this information to discuss the risks, benefits and alternatives of nonoperative and operative treatments.

*The correct answer is D.*

#### References

Dinham JM, Meggitt BF. Trigger thumbs in children. A review of the natural history and indications for treatment in 105 patients. *J Bone Joint Surg Br.*1974;56:153-5.56153 1974  
Rodgers WB, Waters PM. Incidence of trigger digits in newborns. *J Hand Surg [Am].*1994;19:364-8.19364 1994  
Slakey JB, Hennrikus WL. Acquired thumb flexion contracture in children: congenital trigger thumb. *J Bone Joint Surg Br.* 1996;78:481-3.

## “Create Your Own” Self-Study Exams

Create and take self study exams of previous OITE questions by picking classifications and number of items. Go there now!

Visit: <http://www3.aaos.org/education/exams/exam.cfm>

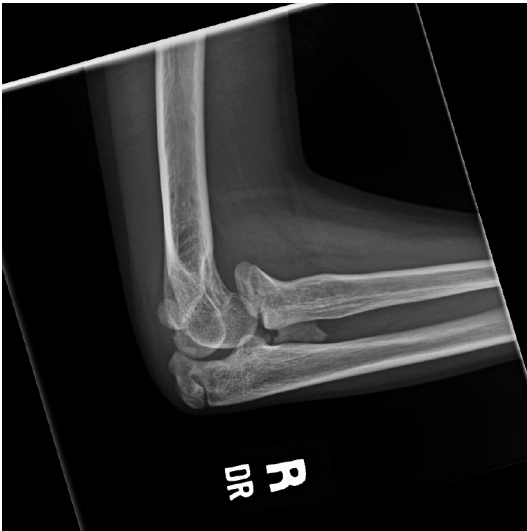Continued on page 10

## Challenging Cases: What Would You Do?

continued from page nine

### CASE #2

A 7 year old patient had elbow trauma 9 months ago. His elbow flexion is limited to 110 degrees, and he lacks 30 degrees of extension. He has 30 degrees of supination, and 50 degrees of pronation. Which of the following statements is true?



- A. There is no risk of osteonecrosis of the proximal radial epiphysis with corrective osteotomy and fixation
- B. The “cam-effect” is likely contributing to his poor forearm rotation
- C. Excision of the radial head will allow full motion return with no long term issues at the wrist
- D. The residual deformity is congenital and likely unrelated to the traumatic event history
- E. Chronic problems with this deformity are likely postero-lateral rotary instability (PLRI) of the elbow

Your Response: \_\_\_\_

#### Discussion

Radial neck malunions are difficult problems. If the range of motion is functional (some quote 30-130 deg flexion/extension, 50 deg supination, 50 degrees pronation), then no treatment is recommended. If there is poor motion, but no pain, then the risks of surgery relative to the expected gain in motion or function may lead surgeons to avoid surgery. Surgical approaches to the proximal radius in children endanger the blood supply to the developing proximal radial epiphysis and thus carry a high risk of osteonecrosis. Translational deformities disrupt the rotational arc of the radius and this cam-effect is believed to contribute to limitations of forearm rotation. Excision of the radial head in children removes the proximal physis and some of the

### CASE #2, continued

ligamentous connections between the proximal radius and ulna, and thus may disrupt the normal balanced growth of the forearm, resulting in proximal migration of the radius relative to the ulna at the wrist. Congenital radial head dislocations are typically posterolateral. Anterior translation of the radial head relative to the capitellum is not a predisposing condition for PLRI of the elbow. Residual cubitus varus deformity after pediatric elbow trauma has been described as a potential contributing factor to PLRI development.

The correct answer is B.

#### References

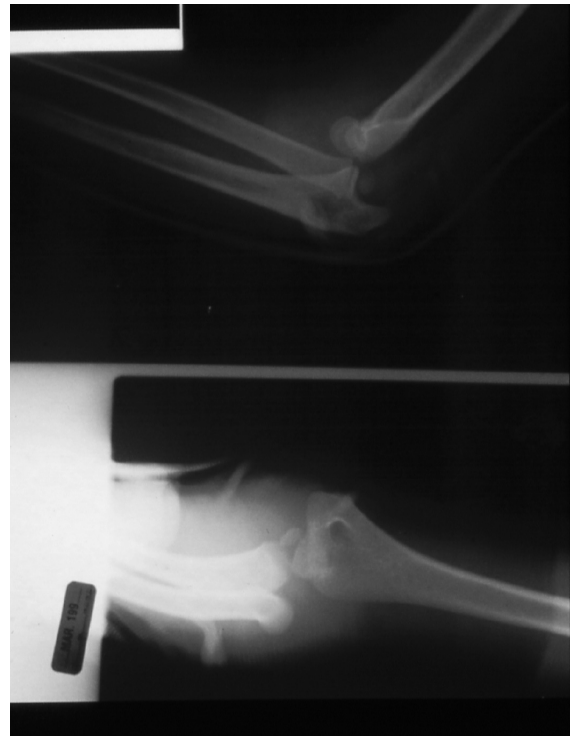Neck Osteotomy for Malunion of Neglected Radial Neck Fractures in Children: A Report of 2 Cases Ceroni, Dimitri; Campos, José; Dahl-Farhoumand, Agnes; Holveck, Jérôme; Kaelin, André *Journal of Pediatric Orthopaedics*. 30(7):649-654, October/November 2010

Radial Neck Fracture Nonunion in Children. Waters, Peter M.; Stewart, Susan L. *Journal of Pediatric Orthopaedics*. 21(5):570-576, September/October 2001.

### CASE #3

A 9 yo boy sustains this injury. What structure can get trapped in the joint during closed reduction?

Figure 1



Continued on next page

## Challenging Cases: What Would You Do?

continued from previous page

### CASE #3, continued

- A. The annular ligament
- B. The medial epicondyle
- C. The lateral epicondyle
- D. The ulnar collateral ligament
- E. The capitellum

Your Response: \_\_\_\_

#### Discussion

50% of medial epicondyle fractures occur with elbow dislocations. They can become incarcerated in the joint during dislocation itself, or during closed reduction.

The correct answer is B.

#### References

Scherl, SA, ed.: Surgical Management of Pediatric Long-Bone Fractures, AAOS, 2009, p. 28.

What is the maneuver to attempt to remove the entrapped structure from the elbow joint?

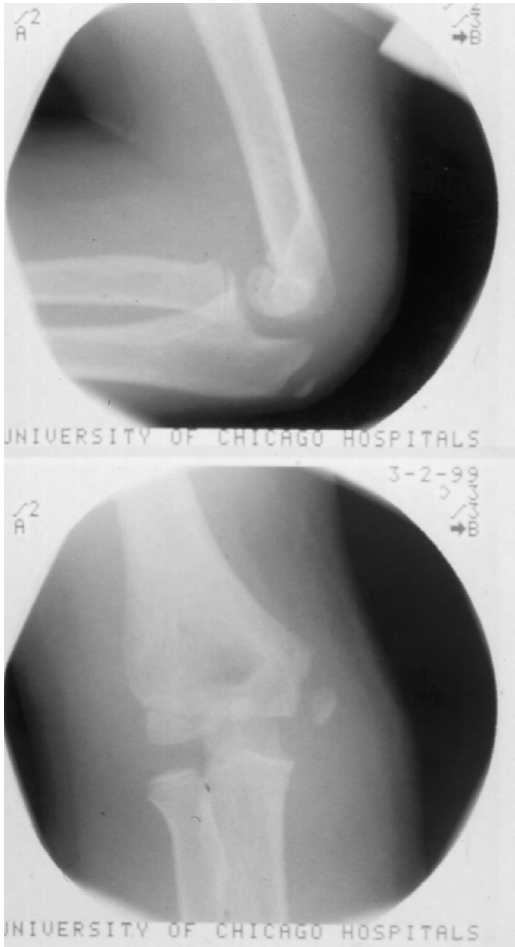


Figure 2

### CASE #3, continued

- A. Valgus stress on elbow, pronation of forearm, plantar flexion of fingers
- B. Varus stress on elbow, supination of forearm, dorsiflexion of wrist
- C. Varus stress on elbow, pronation of forearm, plantar flexion of fingers
- D. Valgus stress on elbow, supination of forearm, dorsiflexion of wrist and fingers
- E. Supination of the forearm and flexion of the elbow and fingers

Your Response: \_\_\_\_

#### Discussion

Though often considered an indication for surgery, attempt at extraction of an entrapped medial epicondyle can be performed with the above maneuver.

The correct answer is D.

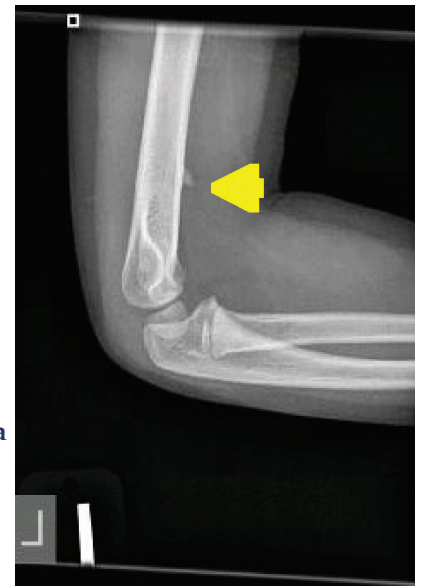
#### References

Scherl, SA, ed.: Surgical Management of Pediatric Long-Bone Fractures, AAOS, 2009, p. 28.

### CASE #4

Which of the following is not true of the structure at the arrow?

- A. It is often an incidental finding
- B. It can be a cause of median nerve compression
- C. It can be a cause of brachial artery compression
- D. It is an osteochondroma
- E. A similar structure is found in cats



Your Response: \_\_\_\_

Continued on page 12



## Challenging Cases: What Would You Do?

continued from page eleven

### CASE #4, continued

#### Discussion

This is a supracondylar process. Typically found incidentally, but they can cause median nerve/brachial artery compression. Osteochondroma is in the differential. Cats, lemurs, and a few other mammals also have supracondylar processes.

The correct answer is D.

#### References

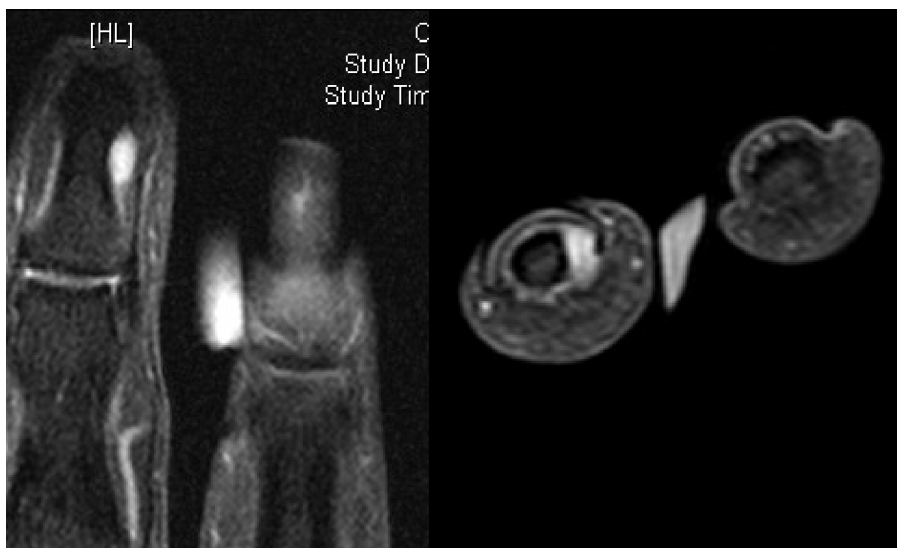
Subasi, M., et al., Supracondylar Process of the Humerus, *Acta Orthopaedica Belgica*, Vol. 68:1, 2002, p. 72-5.

### CASE #5

A 9 year old girl presents with a painful finger. She has noticed a bruise under the nail but does not remember any specific trauma. The pain has been gradually worsening and is not significant. On questioning, she noticed that it hurts more when she goes out in the cold. Xr are normal, MRI below. The most appropriate treatment would be:

- A. Drilling of the nailbed to relieve the hematoma
- B. Wide excision and radiation
- C. Primary amputation
- D. Local excision
- E. Splinting for 6-8 weeks

Your Response: \_\_\_\_



#### Discussion

This patient has a glomus tumor. Although they may exist

### CASE #5, continued

on the extremities, the nailbed is a classic location. These are benign vascular lesions which respond to excision. The bluish blush seen under the nailbed is consistent with the vascular nature of the lesion. The absence of known trauma makes a hematoma unlikely. The mri shows an enhancing lesion consistent with a glomus tumor. Cases of glomangiosarcoma, a malignant version, are rare, but tissue should be sent to pathology to confirm the diagnosis.

The correct answer is D.

#### References

Paliogiannis P, Trignano E, Trignano M. Surgical management of the glomus tumors of the fingers: a single center experience. *Ann Ital Chir.* 2011 Nov-Dec;82(6):465-8.  
Smalberger GJ, Suszko JW, Khachemoune A. Painful growth on right index finger. Subungual glomus tumor. *Dermatol Online J.* 2011 Sep 15;17(9):12.  
Oh SD, Stephenson D, Schnall S, Fassola I, Dinh P. Malignant glomus tumor of the hand. *Appl Immunohistochem Mol Morphol.* 2009 May;17(3):264-9.

### CASE #6

All of the following are potential complications of lateral condyle fractures except:

- A. Avascular necrosis
- B. Nonunion
- C. Tardy ulnar nerve palsy
- D. Severe cubitus varus
- E. Late displacement of a nondisplaced fracture

Your Response: \_\_\_\_

#### Discussion

The lateral condyle of the humerus receives its blood supply from the posterior musculature. Extensive posterior dissection may result in avascular necrosis. Possibly because of their tenuous blood supply and continuity with the joint and thus synovial fluid, a delay in healing or nonunion is not rare. A growth disturbance related to nonunion may result in late cubitus valgus, causing tension on the ulnar nerve and thus a tardy nerve palsy. Fractures treated nonoperatively need close monitoring, as late displacement is not uncommon. Cubitus varus is typically a

Continued on next page

## Challenging Cases: What Would You Do?

*continued from previous page*

### CASE #6, continued

complication of supracondylar fractures, although mild cubitus varus may occur after lateral condyle fractures, and is considered an example of growth acceleration of the lateral distal humerus related to fracture.

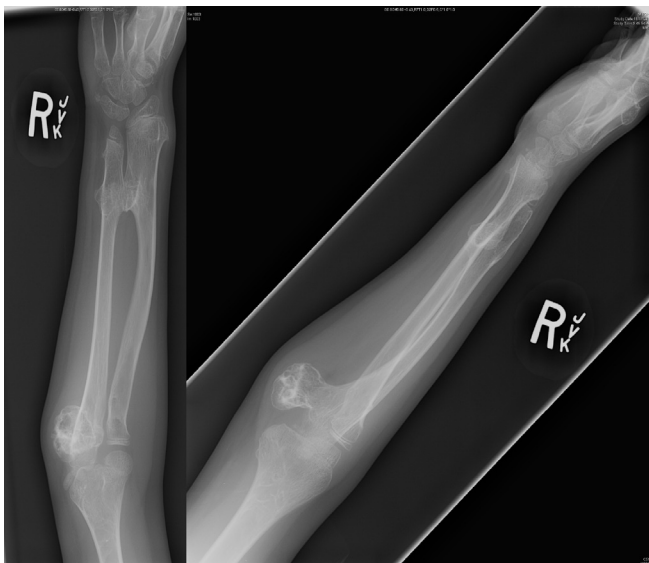
*The correct answer is D.*

#### References

Sullivan JA. Fractures of the lateral condyle of the humerus. *J Am Acad Orthop Surg.* 2006 Jan;14(1):58-62. Storm SW, Williams DP, Khoury J, Lubahn JD. Elbow deformities after fracture. *Hand Clin.* 2006 Feb;22(1):121-9. Weiss JM, Graves S, Yang S, Mendelsohn E, Kay RM, Skaggs DL. A new classification system predictive of complications in surgically treated pediatric humeral lateral condyle fractures. *J Pediatr Orthop.* 2009 Sep;29(6):602-5.

### CASE #7

A 9 year old child presents with a non painful bump on his arm. Examination reveals a fixed mass as well as limited rotation (supination and pronation 40 degrees from neutral) with a normal neurologic exam. Radiographs are as shown. The most appropriate initial treatment is:



- A. Biopsy of the proximal lesion
- B. Wide excision of proximal and distal lesions
- C. Ulnar lengthening and wrist fusion
- D. Observation
- E. Synostosis of the forearm

*Your Response:* \_\_\_\_

### CASE #7, continued

#### Discussion

This patient has multiple exostosis, an autosomal dominant condition. Radiographs are characteristic, therefore biopsy is not required. Since the lesion is not symptomatic, excision is not mandatory, particularly a wide excision of both lesions. While an ulnar lengthening is occasionally recommended in severe deformity, this is usually combined with a distal radial osteotomy, not a wrist fusion. Forming a “one bone forearm” is not a usual option for this condition when the radial head is located.

*The correct answer is D.*

#### References

Steiber J and Dormans J. Manifestations of hereditary multiple exostoses. *JAAOS* 2005; 13:110-120.

### CASE #8

A 4 year old female has difficulty abducting her right arm beyond 90 degrees. She was delivered via C-section after failing to progress during a very challenging delivery. Physical examination demonstrated apparently normal function in both forearms and hands; she can actively flex and extend her elbow without difficulty. Chest x-ray was recently obtained to evaluate for pneumonia. Incidental finding of cervical fusions was noted (Figure 1). The most likely cause of her limited arm motion is:

- A. Klumpke Brachial Plexopathy
- B. Erb's Brachial Plexopathy
- C. Cervical Radiculopathy
- D. Sprengel Deformity
- E. Thoracic Outlet Syndrome

*Your Response:* \_\_\_\_

#### Discussion

This child has congenitally elevated scapula otherwise noted as a Sprengel deformity. This anomaly has often been seen with children with congenital cervical fusions and other congenital abnormalities. Treatment can include observation if the cosmetic deformity is not too severe and if arm function is good. A Woodward procedure can be performed to move the scapula distally and allow forward abduction and extension. Thoracic outlet syndrome can occur acutely when correcting the deformity as a result of the clavicle being drawn on to the first rib.

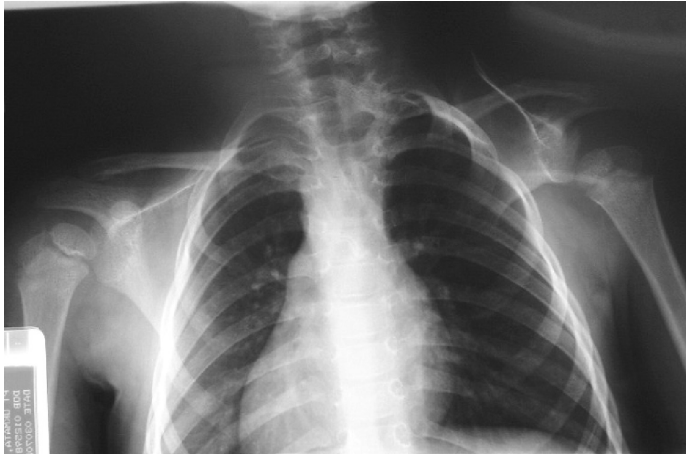
*Continued on page 14*

## Challenging Cases: What Would You Do?

continued from page thirteen

### CASE #8, continued

Figure 1



The correct answer is D.

#### References

- 1: Ahmad AA. Surgical correction of severe Sprengel deformity to allow greater postoperative range of shoulder abduction. *J Pediatr Orthop.* 2010 Sep;30(6):575-81.
- 2: Tsirikos AI, McMaster MJ. Congenital anomalies of the ribs and chest wall associated with congenital deformities of the spine. *J Bone Joint Surg Am.* 2005 Nov;87(11):2523-36.

### CASE #9

A 3 year old girl fell off her scooter and “bumped” her arm when she fell on the point of her elbow. She was taken to the emergency room and was examined. She had slight tenderness over her olecranon and limited pronation and supination; which was not painful. Radiographs were obtained, the next best step in this patient’s treatment is:

- A. Examine the other elbow clinically and radiographically
- B. Obtain MRI to assess location of the radial head
- C. Attempt closed reduction in ED
- D. Open reduction and pinning with transcapsular pin
- E. Ligamentous Bell Tawse Reconstruction

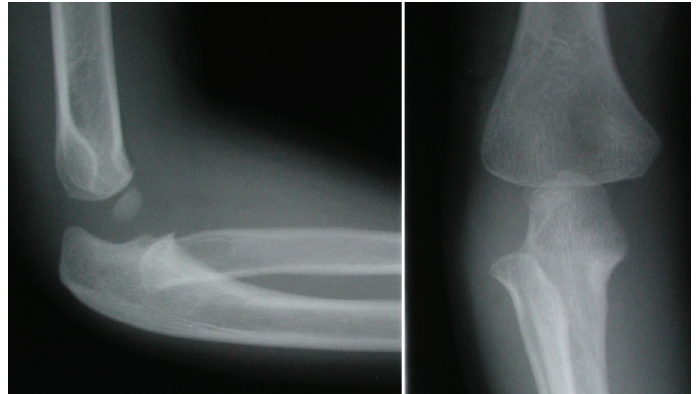
Your Response: \_\_\_\_

#### Discussion

The radiographs reveal a posteriorly dislocated radial head. The differential diagnosis favors a congenital etiology versus post traumatic. Most radial head dislocations from trauma are anterior or lateral and are the result of more significant

### CASE #9, continued

trauma then a simple fall on the point of the elbow. A high percentage of children with posterolateral dislocations have this condition bilaterally and thus confirms the diagnosis of congenital etiology. In a congenital radial head dislocation, the radial neck is often curved and the head may be rounded in a “bullet” shape and should be left dislocated unless diagnosed very early and treated by highly experienced surgeons.



The correct answer is A.

#### References

- Sachar K, Mih AD. Congenital radial head dislocations. *Hand Clin.* 1998 Feb;14(1):39-47.

### CASE #10

Having recently moved to the United States, a family brings their 4-year-old daughter to the office concerned about the appearance of her right arm. They inform you that she sustained an injury last year and was treated non-operatively with long-arm casting for 4 weeks. Original images are not available. After comparing new radiographs of her right elbow (Figure A) with her normal left elbow (Figure B), you inform them:

- A. There is most likely a growth arrest of the distal humeral physis and an MRI or CT scan is necessary to confirm the diagnosis
- B. This deformity puts her at risk for tardy ulnar nerve palsy
- C. Based on her young age, the deformity is likely to remodel completely as she grows
- D. Her deformity is likely to limit her elbow extension
- E. Her deformity is likely to persist as a cosmetic issue with mild functional loss

Your Response: \_\_\_\_

Continued on next page



## Challenging Cases: What Would You Do?

*continued from previous page*

### CASE #10, continued

Figure A

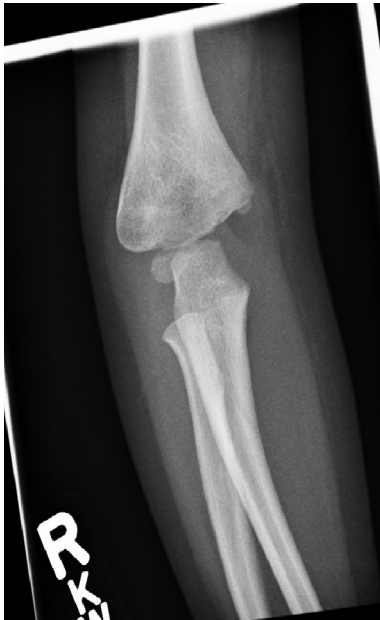
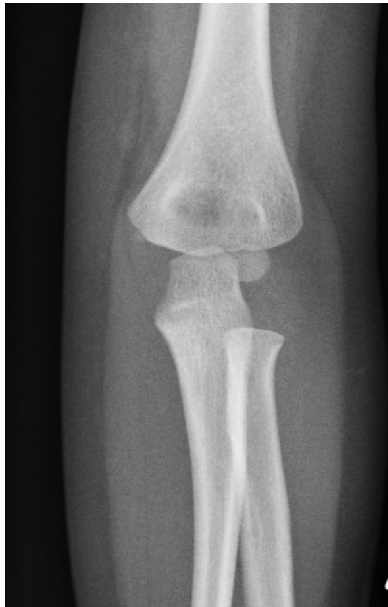
Figure B



#### Discussion

This girl sustained a supracondylar distal humerus fracture that healed in varus and extension. Although flexion type injuries can occur, greater than 90% of fractures are extension type. According to Gartland's classification, Type I fractures are nondisplaced; Type II fractures are angulated with the posterior cortex intact; and Type III fractures are completely displaced. Because the distal humeral physis contributes only 20% of the growth of the humerus, malreduced fractures are unlikely to remodel, especially in the coronal plane. Reduction, therefore, is recommended for displaced fractures. If casting alone is used, elbow flexion of greater than 120 degrees is typically required to maintain reduction, and this position increases the risk of ischemia and compartment syndrome. Percutaneous pinning is considered a safer alternative to stabilize reduced fractures and, thus, avoid the risk of hyperflexion in a cast. Since this girl was treated with casting alone, malunion likely occurred as evidenced by the asymmetric humero-ulnar angle (angle between the mid-humeral line and a line drawn down the ulna) and Baumann's angle (angle created by a perpendicular to the humerus axis and a line drawn along the growth plate of the lateral condyle) on the AP image. Cubitus varus, or gunstock deformity, is primarily a cosmetic deformity seen after malreduced supracondylar fractures; whereas, cubitus valgus is more likely to occur after lateral condyle fractures and may be associated with tardy ulnar nerve palsy. Cubitus varus can have functional consequences if the hyperextension is severe and limits elbow flexion to a non-functional range (cannot get hand to mouth), and has

### CASE #10, continued

been noted to predispose patients to lateral condyle fractures and late posterolateral rotatory instability of the elbow.

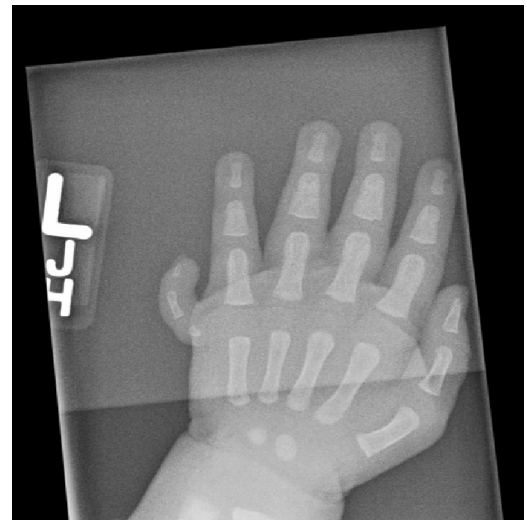
*Preferred response is E.*

#### References

Otsuka NY, Kasser JR: Supracondylar fractures of the humerus in children. *J Am AcadOrthopSurg* 1997;5(1):19-26.  
Camp J, Ishizue K, Gomez M, et al: Alteration of Baumann's angle by humeral position: Implications for treatment of supracondylar humerus fractures. *J PediatrOrthop*1993;13:94-97.

### CASE #11

An infant presents with the hand deformity in the figure below. Which of the following is true?



- A. This is an example of preaxial polydactyly and typically follows autosomal dominant inheritance
- B. The digit should be excised with suture ligation technique at approximately one year of age
- C. Excision of the extra digit carries the risk of painful neuroma
- D. This is an example of postaxial polydactyly which is more common in Caucasian females than African-American males
- E. Foot polydactyly is more likely to occur with preaxial hand polydactyly than postaxial

Your Response: \_\_\_\_

*Continued on page 16*

## Challenging Cases: What Would You Do?

continued from page fifteen

### CASE #11, continued

#### Discussion

This is an example of postaxial polydactyly, or ulnar-sided duplication. It is more common in African-Americans than Caucasians, males more than females. Although usually transmitted as autosomal dominant, autosomal recessive transmission and associated syndromes may be seen, especially in white children. The duplicated digit can be fully developed (type A) or rudimentary and pedunculated (type B). Suture ligation can be used in the newborn nursery to remove type B digits; however, surgical excision is recommended for older children or more developed digits. Painful neuromas can occur after either treatment. Preaxial polydactyly, or thumb duplication, is usually sporadic, more common in Asian or white children than black children, and affects males more than females.

*Preferred response is C.*

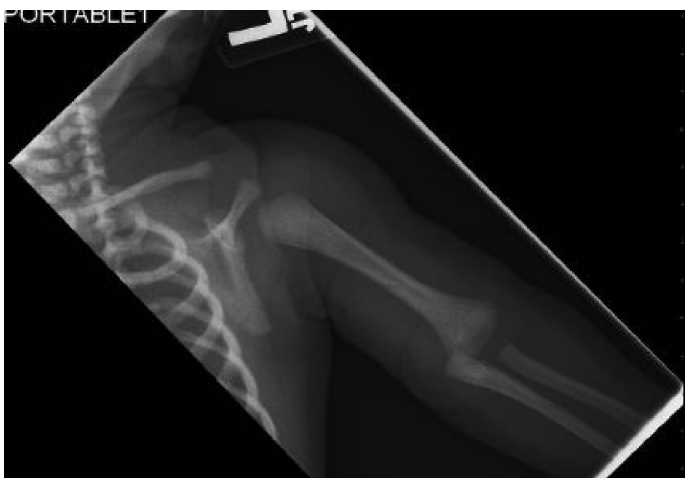#### References

Katz K, Linder N: Postaxial type B polydactyly treated by excision in the neonatal nursery. *J Pediatr Orthop* 2011 Jun;31(4):448-449.  
Watson BT, Hennrikus WL: Postaxial type-B polydactyly. *J Bone Joint Surg Am* 1997;79:65-68.

### CASE #12

You are consulted in the nursery to evaluate a newborn who is not moving the left upper extremity after prolonged labor. The child holds the left shoulder adducted and the elbow extended with no active motion of these joints. There is some finger and wrist flexion and extension noted. Any attempt at ROM of the limb elicits crying and attempted withdrawal.

A plain film of the left upper extremity is shown here:



### CASE #12, continued

Treatment should consist of:

- Pinning of the sleeve to the shirt with follow up exam and Xray in 10-14 days
- Observe for return of biceps function by 3 months
- MRI of the brachial plexus
- Transfer to OR for closed reduction and pinning
- Apply a functional brace

*Your Response: \_\_\_\_*

#### Discussion

This child's Xray shows medial displacement and varus malpositioning of the unossified distal humeral epiphysis with associated soft tissue swelling. This is a displaced distal humerus physal separation fracture. This is an uncommon birth fracture and can be easily missed or mistaken for a non-displaced fracture or brachial plexus palsy. This child was taken to the OR for an arthrogram of the elbow, closed reduction, and percutaneous pinning of the epiphyseal fracture. Recognition of the condition may prevent complications such as compartment syndrome. Cubitus varus is common, even with operative treatment.

*Preferred response is D.*

#### References

Oh CW, Park BC, Ihn JC, Kyung HS. Fracture separation of the distal humeral epiphysis in children younger than three years old. *J Pediatr Orthop*. 2000 Mar-Apr;20(2):173-6.

### CASE #13

An 8 year old baseball pitcher complains of activity related elbow pain. His radiographs demonstrate fragmentation of the entire capitellum. Which one of the following is the most likely diagnosis?

- Osteochondritis Dissicans
- Panner's Disease
- Congenital radial head dislocation
- Proximal radioulnar synostosis
- Avascular Necrosis

*Your Response: \_\_\_\_*

#### Discussion

Panner's Disease is an osteochondrosis of the capitellum. It typically occurs in children under the age of ten years who are involved in repetitive sporting activities.

*The correct answer is B.*



# Technology Corner for Orthopaedic Residents

By: Orrin I. Franko, MD

In last month's "tech corner" I focused on 5 free "must have apps" for orthopaedic residents: AO Surgery Reference, AO Classification, OrthoEvent, Epocrates, and Google Translate. At the time of writing, there were about 74 orthopaedic apps available for iPad and Android, yet in the past 6 months the number has expanded to over 200! In this issue, I will focus on 5 apps that offer some of the greatest value to residents in the clinical arena. Since the publication of the last POSNA Resident Review, I have launched a website dedicated to reviewing orthopaedic apps: [www.TopOrthoApps.com](http://www.TopOrthoApps.com). For those interested in learning more about various apps for your mobile device, please visit the site for reviews and recommendations.

## BoneFeed

This app is part of a family of RSS-reader applications for orthopaedic-related publications. The user can customize which feeds are presented, including JBJS-Am, JBJS-Br, CORR, JHS-Am, Spine, JPO, and many more. The feeds allow the user to review all current abstracts, view the full text article directly from the journal website (if you have online access), post comments, or share the article via Twitter, Facebook, or email. Overall, this app is a simple and intuitive way for orthopaedic residents to keep up-to-date with the latest publications during periods of "micro-boredom" and to identify articles they may want to read at a later time.

**Availability:** iPhone, Android

**Strengths:** scan abstracts from all major orthopaedic journals

**Limitations:** no full-text availability

**Cost:** Free (iPhone) or \$1.99 (Android)

## Campbell's Operative Orthopaedics

I am happy to see that Campbell's is the first orthopaedic text book that has partially transitioned to the digital era. I say "partially" because this app is not the complete 4-volume text, rather it includes "core techniques;" brief summaries of 242 common surgical and bedside procedures accompanied by images and videos. In addition to the many brief entries, some topics are reviewed more thoroughly with 20-30 unique images and videos up to 15-20 minutes in length that demonstrate how to perform full surgical procedures, such as femoral nailing, ACL reconstruction, SLAP repair, rotator cuff repair, chevron osteotomy, compartment syndrome fasciotomy, shoulder hemiarthroplasty, and carpal tunnel release. The app has a very good search feature that scans all topic titles and text within the app. Although considered an expensive app at \$100, compare this to list price of nearly \$800 for the 4-volume print version. I would encourage any residents considering this purchase to review the topics in the app to ensure they are not disappointed with the limited available information.

**Availability:** iPhone

**Strengths:** familiar surgical reference, 242 procedures, images and videos included

**Limitations:** not comparable to full text reference, expensive

**Cost:** \$100

## CORE – Clinical Orthopedic Exam

CORE has set the standard for a clinical exam app. Divided by body part, body region, alphabetical, favorites, or search – the app contains a database of nearly 250 clinical tests which includes a purpose, instructions, video demo, and test properties. The most striking

feature of this app, in addition to the vast collection of tests and videos, is actually the "properties" tab: for every test, data is presented for the sensitivity, specificity, likelihood ratio, accuracy and other relevant statistical tests based on primary literature references. In addition, by selecting the primary reference the user is directed to the full literature source with full abstract text. This is a feature that I have not seen replicated by any other orthopaedic material. The descriptions and videos are clear and accurate, from my review. This app is incredibly valuable to a resident learning the plethora of specialized orthopaedic tests and maneuvers.

**Availability:** iPhone, iPad, Android

**Strengths:** Comprehensive list, videos included, statistical properties with references

**Limitations:** Cost, additional \$7.99 for downloadable videos

**Cost:** \$39.99

## Simple Goniometer

Why guess when you can measure? This app is one of a series of goniometers developed for the iPhone and uses the phone's internal accelerometer to mimic a goniometer for clinical measurements. I find it most useful for objectively quantifying pre- and post-operative total knee arthroplasty range of motion. The results are accurate and precise, and correlate well with standard goniometric measurements. The app only has three functions: set, hold, and reset and is simple to use. Although accuracy depends on the calibration of your device, the app does what it says and allows for precise and objective measurements when a standard goniometer is unavailable.

**Availability:** iPhone

**Strengths:** quick and objective range of motion measurements

**Limitations:** not ideal for small joints of the hand or foot

**Cost:** \$0.99

*Continued on page 18*



## Technology Corner for Orthopaedic Residents

*continued from previous page*

### Ortho Traumapedia

This app is the ideal complement to any student, resident, fellow, or attending taking general orthopaedic trauma call. The app has a simple and intuitive user interface separated into either dislocations or fractures and would be familiar to any resident who has used a popular fracture reference handbook. Each topic is divided into four sub-topics: facts, image, classify, and treat. With an easy-to-read bullet format, the user can quickly glean the most critical facts about a particular fracture, answer common “pimp” questions, understand how to read images with relevant annotations, and review various classification systems for a particular injury. Overall, the material appears to be consistent with most other orthopaedic trauma texts, although no references are provided.

**Availability:** iPhone

**Strengths:** complete fracture guide with image annotations and classification data

**Limitations:** bullet-point format with limited information

**Cost:** \$9.99



**2012 IPOS**  
**Nov. 28 - Dec. 1, 2012**  
**Loews Royal Pacific Resort**  
**Universal Studios,**  
**Orlando, Florida**

## IPOS 2011 Review

The International Pediatric Orthopaedic Symposium (IPOS) was held for the eighth time in Orlando this past December. Once again, attendance increased to set a new record. This past year there were 341 attendees, and 68 faculty. There were 12 didactic sessions, and 47 breakout sessions, with many again having an emphasis on surgical skills and hands-on labs. IPOS is designed to be an interactive symposium that provides educational experiences for learners of all levels- from the novice to the practicing expert. Resident participation in IPOS is key to both the success of the meeting and the future success of pediatric orthopaedics, as during the meeting residents may get interested in pediatric orthopaedics as a career choice. POSNA has established a resident mentoring program for residents attending the IPOS meeting to pair residents with pediatric orthopaedic faculty members. Following are some comments from a few residents who attended IPOS 2011.

*IPOS 2011 was highly recommended by an attending and a senior colleague at my program. They foretold a second-to-none mix of education, professional connections and fun. Unlike any course I've attended before, IPOS blended a curriculum appropriate for all attendees. As a resident I was able to learn from every session, meanwhile I was sitting next to practicing orthopods whom I assume were learning equally as much. Amongst the most beneficial aspects of the course was the opportunity for connecting with other interested residents, current fellows and active attendings; all of whom are influencing the direction of pediatric orthopaedics. By participating in the symposium I therefore had the feeling I was at the cutting edge of pediatric orthopaedic care. An additional unique opportunity IPOS provides is the faculty mentorship program. I was paired with a course faculty member who subsequently developed a personal level of comfort such that I could sit alongside and discuss the intricacies of the field with a leading member of the pediatric orthopaedic community.*

*I would not hesitate to recommend IPOS to any of my colleagues, whether they are interested in peds ortho or not. The experience provides an incomparable method of learning up-to-date content in the field of pediatric orthopaedics, alongside your resident peer, through expert attendings.*

Jason E. Jagodzinski, MD  
PGY-3 Resident  
Loyola University  
Dept of Orthopaedic Surgery  
Chicago, IL

*I would like to thank you for the opportunity to attend this year's IPOS on a scholarship. I was very pleased from the moment I read about the mentor/mentee program. As a foreigner, and as a resident, for me it was very important to receive advice and guidance at the symposium, as well as help in further decisions regarding my fellowship or later on my practice.*

*My mentor was Dr. Schwend, and I had the chance to speak with him and share my impressions. We talked about my future goals and plans and the best ways to accomplish them. He was very kind, and introduced me to other members of the faculty as well.*

*This has been one of the academic highlights of my residency; and the chance to listen to the people whose names I recognized from the literature, talking about the things they are obviously passionate about was fascinating. I really enjoyed the smaller sessions and the breakouts, especially the hands-on workshops as they really gave me the chance to get close to people who were all more than willing to share their experience and teach.*

*Thank you for caring about the residents and their needs.*

Ana María Serrano MD  
PGY 4 Orthopaedic resident  
ABC Medical Center  
Mexico City

*Continued on page 19*

## IPOS 2011 Review continued from page eighteen

This year I attended the IPOS meeting as a third year resident. I went to the meeting with an interest in pediatric orthopaedics, hoping that it would be an educational experience and could help me guide me to decide if pediatric orthopaedics was the subspecialty for me. The interactive educational conference exceeded all of my expectations. This educational conference was the fourth orthopaedic conference that I have attended during residency and it was by far the best. The format is a mix of didactic lectures, panel discussions, small group surgical technique labs, and discussion groups. This combination created an interactive environment for learning and meeting some of the leaders in the field of pediatric orthopaedic surgery. Each lecture placed a heavy emphasis on

learner participation and served more as an interactive seminar than a lecture. I found this environment highly conducive to learning. The breakout sessions allowed for some hands-on learning with implants and surgical techniques, led by well respected pediatric orthopedists. The discussion groups were relevant, interesting, and allowed me to learn how the experts approach particular clinical scenarios. The pediatric orthopaedic community is smaller, allowing for friendly collaboration and "bouncing" thoughts off one another. This collaboration was clearly evident during the "tough" clinical case discussions. The faculty consisted not only of the "giants" of pediatric orthopaedics, whose articles and books I have read, but also some new and upcoming leaders. The faculty were approachable and engaging during breakout sessions, but also during breaks throughout the conference.

Another great part of the meeting was the emphasis placed on new orthopaedist anticipating a possible career in pediatrics. One breakout session was totally dedicated to educate on what a career in pediatric orthopaedics would be like. The discussion panel provided advice on how

and what to look for in a fellowship and job, balancing clinical time and research during a career, the future of pediatric orthopaedics, and addressed issues they encountered early in their careers. I left the session feeling I had gained an inside track regarding how best to succeed in fellowship and beyond, whether it's as a pediatric orthopaedist or something else. The conference also arranged a mentorship program for residents, aimed at promoting a career in pediatric orthopaedics. In this program, interested residents were paired with a faculty member for a breakfast one morning. This was a great opportunity for a "one-on-one" question and answer session, and even more so to gain a mentor within the field.

In summary, IPOS was unique and very informative for learning about the treatment of pediatric orthopaedic conditions. I left IPOS with an increased interest in a pediatric orthopaedic career, and I would encourage all residents to attend.

F. Keith Gettys, MD  
PGY-3 Resident  
Carolinas Medical Center  
Charlotte, NC

### 2012 Editorial Board

**Pablo Castaneda, MD**  
Mexico City, Mexico

**Craig Ebersson, MD**  
Providence, RI

**Ron El-Hawary, MD**  
Halifax, NS, Canada

**John (Jack) Flynn, MD**  
Philadelphia, PA

**Chip Iwinski, MD**  
Lexington, KY

**Thomas McPartland, MD**  
East Brunswick, NJ

**Todd Milbrandt, MD**  
Lexington, KY

**Kenneth Noonan, MD**  
Madison, WI

**Kristan Pierz, MD**  
Hartford, CT

**Susan Scherl, MD**  
Omaha, NE

**Brian Smith, MD**  
New Haven, CT

**EDITOR: Steven L. Frick, MD**  
Charlotte, NC



**2012 POSNA  
ONE DAY COURSE  
Adolescent Hip Disorders  
May 16, 2012  
Hyatt Regency  
Denver, Colorado**

**2012 POSNA  
ANNUAL MEETING  
May 16 - 19, 2012  
Hyatt Regency  
Denver, Colorado**

Visit the POSNA website at  
[www.posna.org](http://www.posna.org) for details.